



E-ISSN: 2706-9575  
P-ISSN: 2706-9567  
IJARM 2020; 2(2): 166-169  
Received: 12-05-2020  
Accepted: 22-06-2020

**Dr. Anubhav Gupta**  
Assistant Professor,  
Department of General  
Medicine, JNUIMSRC, Jaipur,  
Rajasthan, India

**Dr. Kanika Vij**  
Department of Clinical  
Microbiology (Research  
Methodology and Statistics),  
Rajasthan, India

## **A study on occurrence of cardiovascular complications among adult patients with ST elevation anterior wall myocardial infarction in the presence or absence of reciprocal lead ECG changes**

**Dr. Anubhav Gupta and Dr. Kanika Vij**

**DOI:** <https://doi.org/10.22271/27069567.2020.v2.i2c.63>

### **Abstract**

Acute anterior wall ST elevation MI with reciprocal lead changes are associated with more extensive ischemic area or larger infarction & more complications. The present research was thus conducted to study the occurrence of cardiovascular events in ST elevation anterior wall myocardial infarction in the presence or absence of reciprocal lead ECG changes.

**Keywords:** cardiovascular events, STEMI, MI, reciprocal lead changes

### **Introduction**

Multiple risk factors are implicated for this rise, ranging from cigarette smoking, hypertension, diabetes mellitus, and obesity to various psychosocial stresses imposed by social dynamics and urbanisation <sup>[1]</sup>.

Acute Myocardial Infarction (MI) is said to have occurred when there is biochemical evidence of myonecrosis in a patient with chest pain suggestive of coronary ischemia for prolonged period (>30 min). They are classified as ST segment elevation MI and non-ST-segment elevation MI.

ST segment elevated MI (STEMI) represents the most lethal form of myocardial insult. The thrombus results in total cessation of coronary blood flow in the territory of occluded artery that leads to ST segment elevation on the ECG. The classic WHO criterion for an acute myocardial infarction requires that two of the following three elements be present <sup>[2]</sup>: A history suggestive of coronary ischemia for a prolonged period (>30 mins), evolutionary change on serial ECG suggestive of MI and; a rise and fall in serum cardiac markers consistent with myonecrosis.

Many complications can happen following myocardial infarction. Mechanical complication include ventricular septal rupture, papillary muscle rupture, ventricular free wall rupture, development of LV aneurysm, acute mitral regurgitation and circulatory collapse. Electrical complications include tachycardia and bradycardia. Bradycardia includes SA node block and AV node block while tachycardia includes SVT, PSVT, VT and VF. Late complications include post infarction angina, heart failure and pericarditis. The incidence and prognosis of cardiovascular events after MI in the short- and medium-term are among the most widely studied areas in cardiology <sup>[3-7]</sup>. However, there is little information on the incidence and determinants of new adverse cardiovascular events during the long-term clinical course <sup>[8-10]</sup>. Patients with ST elevation in one myocardial zone often have concurrent ST depression in other myocardial zones. Such ST depression may represent pure “mirror image” reciprocal changes or may be indicative of acute ischemia due to coronary artery disease in non-infarct related arteries (“ischemia at a distance”) <sup>[11]</sup>. Interest in reciprocal ECG changes in acute inferior MI has yielded many findings, which have led to broadly differing inferences. Some studies have concluded that reciprocal changes represent an electrophysiological phenomenon related with an injury at the infarct site. Others assume that reciprocal changes are associated with more extensive ischemic area or larger infarction <sup>[12,13]</sup>. Studies have shown that STEMI with reciprocal changes has more complications such as multi vessel disease and severe LV systolic dysfunction <sup>[14]</sup>.

**Corresponding Author:**  
**Dr. Kanika Vij**  
Department of Clinical  
Microbiology (Research  
Methodology and Statistics),  
Rajasthan, India

The present research was thus conducted to study the occurrence of cardiovascular events in ST elevation anterior wall myocardial infarction in the presence or absence of reciprocal lead ECG changes.

**Objectives**

To compare the cardiovascular complications in the presence and absence of reciprocal lead ECG changes.

**Materials and Methods**

Patients admitted in JNUIMSRC, Jaipur with ECG changes suggestive of Anterior wall ST- elevated Myocardial infarction (AW-STEMI) were included in the study. Patients were followed with regular clinical examination on day 1, day 2 and day 3, vitals were monitored and occurrence of any significant clinical events was recorded with a predefined proforma. 2-D echocardiography was performed in all cases to find the evidence of Coronary artery disease. Based on the ECG findings, patients were classified into two groups: MI cases with and without reciprocal ST depression (as per criteria defined below).

**Study Duration**

Dec 2015 to Dec 2016 (1 year)

**Inclusion Criteria**

Patients admitted with Anterior Wall ST Elevation MI in Emergency Department. of Azeezia.

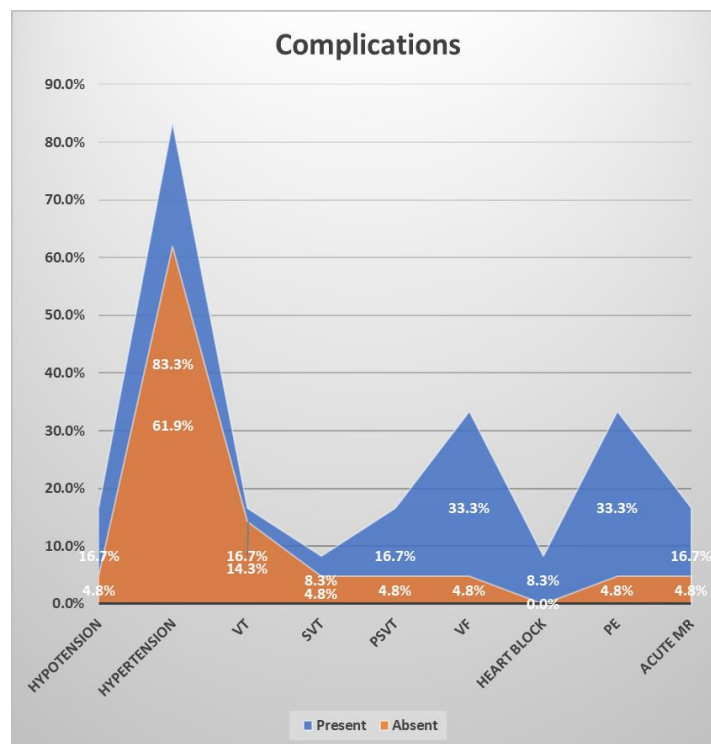
**Exclusion Criteria**

1. Patients with previous history of MI who had undergone PCI or CABG
2. Patients with H/o valvular heart disease

**Results**

**Table 1:** Comparison of complications among cases with and without reciprocal lead changes

Complications	Reciprocal lead Changes		p-value
	Present	Absent	
Hypotension	16.72%	4.81%	0.52
Hypertension	83.31%	61.94%	0.24
VT	16.72%	14.34%	1.00
SVT	8.34%	4.87%	1.00
PSVT	16.72%	4.83%	0.52
VF	33.31%	4.84%	<0.05
Heart Block	8.31%	0.0%	0.33
Pulmonary edema	33.33%	4.81%	<0.05
Acute MR	16.76%	4.82%	0.54



**Graph 1:** Comparison of complications among cases with and without reciprocal lead changes

**Discussion**

Leading cause of death World Wide. Cardiovascular diseases counts for over 17.5 million deaths in 2012. Over 3 quarters of CVD deaths are from low and middle income countries. Risk factors associated with it are cigarette smoking, hypertension, diabetes mellitus, tobacco smoking, excess alcohol, physical inactivity and obesity, sleep disorder, stress. The incidence of MI in India is 64.37/1000 people in men aged 29-69 years. Individuals aged older than 45 years have an eight times greater risk for AMI. In women after menopause Even death rate from heart disease increases, it's not as great as men.

Primary causative factor in the development of AMI is rupture of high-risk atheromatous plaque in the coronary arteries. When exposed to subendothelial collagen and necrotic plaque contents, platelets adhere, become activated, release their granule contents, and aggregate to form microthrombi. They are classified as ST segment elevation MI (STEMI) and Non-ST- segment elevation MI. Obstruction leads to decrease in blood flow to a region of myocardium causing ischemia, and myocardial dysfunction, and eventually—with prolonged vascular compromise —myocyte death. of the anatomic region supplied by it. There are evidences that shows only severe ischaemia sustaining

for 20 to 30 minutes or long lead to myonecrosis. Biochemical evidence of myonecrosis with chest pain implies coronary ischaemia leading to the diagnosis of Acute Myocardial infarction. This results in ST segment myocardial infarction.

- This delay in the onset of permanent myocardial injury provides the rationale for rapid diagnosis in acute MI—to permit early coronary intervention to establish reperfusion and salvage as much “at risk” myocardium as possible.
- Time to elevation of CKMB, cTnT and cTnI is 3 to 12 hrs.
- CK-MB and cTnI peak at 24 hours.
- CK-MB returns to normal in 48-72 hrs, cTnI in 5-10 days, and cTnT in 5 to 14 days.

Complications include ventricular septal rupture, papillary muscle rupture, ventricular free wall rupture, development of LV aneurysm, acute mitral regurgitation and circulatory collapse. Electrical complications include tachycardia and bradycardia. Bradycardia includes SA node block and AV node block while tachycardia includes SVT, PSVT, VT and VF. Late complications include post infarction angina, heart failure and pericarditis. The incidence and prognosis of cardiovascular events after MI in the short- and medium-term are among the most widely studied areas in cardiology. The ST elevation anterior wall myocardial infarction in the presence or absence of reciprocal lead ECG changes.

The significance of ST segment depression in acute myocardial infarction is questionable. ST elevation in myocardial area have contrast ST depression in other myocardial areas. This ST depression reciprocal changes or is indicative of acute ischemia due to coronary artery disease in non-infarct arteries. This has been concluded that reciprocal changes signifies an electrophysiological phenomenon at the injury site or these areas are associated with more bigger ischemic area or larger infarction. STEMI with reciprocal changes has more complications such as multiple vessel disease and severe LV systolic dysfunction. Individuals aged older than 45 years have an eight times greater risk for AMI. In women after menopause Even death rate from heart disease increases, it's not as great as men's. Esrogens protects the females of reproductive age group. The most common co-morbid conditions associated diabetes, hypertension.

The ECG findings of an acute anterior myocardial infarction wall include: ST segment elevation in the anterior leads (V3 and V4) at the J point and may be in the septal or lateral leads, depending on the extent of the MI. Reciprocal ST segment depression in the inferior leads (II, III and aVF). According to the American College of Cardiology/American Heart Association guidelines for STEMI, there must be “new ST segment elevation at the J point in at least two contiguous leads of  $\geq 2$  mm (0.2 mV) in men or 1.5 mm (0.15 mV) in women in leads V2-V3 and/or of  $\geq 1$  mm (0.1 mV) in other contiguous chest leads or the limb leads.” This means 1 millimeter in any two contiguous leads, except leads V2 or V3, where the elevation must be 2 mm in men or 1.5 mm in women.

### Conclusion

The significance of reciprocal ST depression on the electrocardiogram during the course of anterior wall myocardial infarction (MI) remains uncertain, Present study shows that patients with reciprocal ST segment depression

had poor ejection fraction, higher prevalence of multi-vessel CAD, more post-infarction complications and a higher mortality rate than those without reciprocal ST segment depression. Hence we conclude that presence of ST segment depression on ECG is a useful marker to differentiate high risk patients for a more aggressive approach.

### References

1. Senthil KP *et al.* Clinical profile of acute inferior wall myocardial infarction in a semi urban population in India. *Journal of Medicine and Medical Sciences* 2013;4(1):17-21.
2. Antman, Elliott *et al.* Myocardial infarction redefined—a consensus document of the Joint European Society of Cardiology/American College of Cardiology committee for the redefinition of myocardial infarction: the Joint European Society of Cardiology/American College of Cardiology Committee. *Journal of the American College of Cardiology* 2000;36(3):959-969.
3. Chung SC, Gedeberg R, Nicholas O, James S, Jeppsson A, Wolfe C *et al.* Acute myocardial infarction: a comparison of short-term survival in national outcome registries in Sweden and the UK. *Lancet* 2014;383:1305-12.
4. Raposeiras-Roubín S, Abu-Assi E, Cabanas-Grandío P, Agra-Bermejo RM, Gestal-Romari S, Pereira-López E *et al.* Walking beyond the GRACE (Global Registry of Acute Coronary Events) model in the death risk stratification during hospitalization in patients with acute coronary syndrome: what do the AR-G (ACTION [Acute Coronary Treatment and Intervention Outcomes Network] Registry and GWTG [Get With the Guidelines] Database), NCDR (National Cardiovascular Data Registry), and EuroHeart Risk Scores Provide?. *JACC Cardiovasc Interv* 2012;5:1117-25.
5. Arós F, Heras M, Vila J, Sanz H, Ferreira-González I, Permanyer-Miralda G *et al.* Reducción de la mortalidad precoz y a 6 meses en pacientes con IAM en el periodo 1995-2005. Datos de los registros PRIAMHO I, II y MASCARA. *Rev EspCardiol* 2011;64:972-80.
6. Roe MT, Messenger JC, Weintraub WS, Cannon CP, Fonarow GC, Dai D *et al.* Treatments, trends, and outcomes of acute myocardial infarction and percutaneous coronary intervention. *J Am CollCardiol* 2010;56:254-63.
7. Rogers WJ, Frederick PD, Stoehr E, Canto JG, Ornato JP, Gibson CM *et al.* Trends in presenting characteristics and hospital mortality among patients with ST elevation and non-ST elevation myocardial infarction in the National Registry of Myocardial Infarction from 1990 to 2006. *Am Heart J* 2008;156:1026-34.
8. Jernberg T, Hasvold P, Henriksson M, Hjelm H, Thuresson M, Janzon M. Cardiovascular risk in post-myocardial infarction patients: nationwide real world data demonstrate the importance of a long-term perspective. *Eur Heart J* 2015;36:1163-70.
9. Fox KA, Carruthers KF, Dunbar DR, Graham C, Manning JR, De Raedt H *et al.* Underestimated and under-recognized: the late consequences of acute coronary syndrome (GRACE UK-Belgian Study). *Eur Heart J* 2010;31:2755-64.

10. Polonski L, Gasior M, Gierlotka M, Osadnik T, Kalarus Z, Trusz-Gluza M *et al.* A comparison of ST elevation versus non-ST elevation myocardial infarction outcomes in a large registry database: are non-ST myocardial infarctions associated with worse long-term prognoses?. *Int J Cardiol* 2011;152:70-7.
11. Birnbaum Y, Drew BJ. Anatomy and prognosis myocardial infarction: correlation with coronary the electrocardiogram in ST elevation acute *Postgrad Med J* 2003 79:490-504
12. Hlatky MA, Califf RM, Lee KL, Pryor DB, Wagner GS, Rosati RA. Prognostic significance of precordial ST segment depression during inferior acute myocardial infarction. *Am J Cardiol.* 1985; 55:325-329.
13. Berland J, Cribier A, Bahar P, Letac B, Anterior ST. segment depression in inferior myocardial infarction: Correlation with results of intracoronary thrombolysis. *Am. Heart J* 1986; 111:481-488.
14. Parale GP, Kulkarni PM, Khade SK, Athawale S, Vora A. Importance of reciprocal leads in acute myocardial infarction. *JAPI* 200420;52:376-9.