



E-ISSN: 2706-9575
P-ISSN: 2706-9567
IJARM 2020; 2(1): 37-40
Received: 25-01-2020
Accepted: 27-02-2020

Dr. Sumeera Banday
Assistant Professor,
Department of Respiratory
Medicine Hamdard Institute of
Medical Sciences and Research,
Hamdard Nagar, Delhi, India

Dr. Majid Ahmed Talikoti
Assistant Professor,
Department of Surgery, Rama
Medical College, Hospital &
Research Centre, Hapur, Uttar
Pradesh, India

Dr. Jahanara Banday
Associate Professor,
Department of Anaesthesia,
Rama Medical College,
Hospital & Research Centre,
Hapur, Uttar Pradesh, India

Corresponding Author:
Dr. Sumeera Banday
Assistant Professor,
Department of Respiratory
Medicine Hamdard Institute of
Medical Sciences and Research,
Hamdard Nagar, Delhi, India

Bronchial brushings, washings and biopsies in diagnosis of lung collapse: A comparative study

Dr. Sumeera Banday, Dr. Majid Ahmed Talikoti and Dr. Jahanara Banday

DOI: <https://doi.org/10.22271/27069567.2020.v2.i1a.37>

Abstract

Background: To evaluate the utility of fiberoptic bronchoscopy and to compare the sensitivities of bronchial brushings, washings and biopsies in diagnosing the etiology of lung collapse.

Materials and Methods: The present study was carried out on 32 patients attending the OPD of Respiratory Medicine at Hamdard Institute of Medical Sciences and Research. Patients who had persistent opacities in form of collapse in chest radiography were subjected to detailed clinical history, physical examination and routine investigations followed by fiberoptic bronchoscopy provided they met the criteria of our study.

Results: The age of the patients varied from 18 to 75 years and the male: female ratio was 3:1. Malignant causes were diagnosed in 18 (56.25%) out of total 32 cases on bronchial biopsy, 10 cases (31.25%) showed inflammatory changes and in 4 cases significant pathology could not be established through bronchoscopy. Bronchial washing showed 11 true positive, 7 true negative, 3 false positive and 11 false negative cases whereas bronchial brushing showed 18 true positive, 10 true negative, 1 false positive and 3 false negative cases, as confirmed on biopsy. Bronchial brushing showed good sensitivity (85.71%) and specificity (90.90%) compared to bronchial washing which had sensitivity of 53.28% and specificity of 70%.

Conclusions: We conclude that fiberoptic bronchoscopy with bronchial brushing was found to be extremely useful in finding specific etiology of lung collapse.

Keywords: Bronchoscopy, Biopsy, Brushings, Lung collapse

Introduction

In 1897 Gustav Killian, known as the 'Father of Bronchoscopy', reportedly investigated the lower trachea and main stem bronchi using a Kirstein laryngoscope. He called the method 'direct bronchoscopy'. This began the era of bronchoscopy [1]. Endobronchial examination was first carried out in the last decade of nineteenth century for the purpose of removing inhaled foreign bodies. The advent of flexible fiberoptic bronchoscopy (FOB), pioneered by Shigeto Ikeda in 1967, opened new horizons to clinicians. Bronchoscopy is an important entity in the armamentarium of procedures listed in diagnosis of respiratory problems [1]. It is a universally accepted procedure both in the diagnosis and therapy of various pulmonary disorders.

Lung collapse is an air less peripheral gas exchange region, which is an abnormal condition associated with a variety of pulmonary disorders and represents a manifestation of underlying pulmonary pathology rather than a disease entity. Lung collapse most commonly occurs due to bronchial obstruction presenting as a group of clinical, physical and roentgenographic findings. Once the collapse is identified it is imperative to diagnose the etiology of collapse. Therefore, it is necessary to use diagnostic tools such as fiberoptic bronchoscopy to get an accurate diagnosis of underlying cause in a patient presenting with collapse on chest radiograph or CT [2].

The etiological factors are varied and numerous, but all may produce some similar changes at corresponding stages in the development of a bronchial obstruction. The cause may lie wholly within the lumen of the bronchus (eg. foreign body) or within the bronchial wall (malignancy or inflammation) or it may lie entirely outside the wall of the bronchus in the peribronchial or adjacent tissue (lymphadenopathy) [3]. Bronchoscopy allows careful inspection of the bronchial tree for endobronchial lesion and foreign body and also helps in

recovery of deep respiratory secretions, brushing and biopsy which is useful in diagnosis of uncommon infections, neoplasm and other noninfectious causes [4]. FOB not only helps in assessing the disease area but also provides better bacteriological and histological yield thus helping to reach a definite diagnosis.

Materials and Methods

The present prospective study was carried out on 32 patients from July 2014 to January 2016 at OPD of Respiratory Medicine at Hamdard Institute of Medical Sciences and Research after ethical committee clearance. Patients who presented with chest X-ray suggestive of collapse were included in the study. Patient’s history, observations on physical examination and relevant investigations were carried out. Bronchoscopy was carried out using a flexible fiberoptic bronchoscope. Endobronchial lung biopsies were taken. Endobronchial brushings and washings were also obtained. The biopsy specimens were fixed in formalin and Haematoxylin-Eosin stained sections were examined. Special stains including Ziehl-Neelsen, Periodic acid-Schiff (PAS), reticulinetc. Were done wherever required. The brushing smears were stained with May-Grunwalds, Geimsa and Haematoxylin-Eosin stains. The washings were cytocentrifuged and the sediment was used for cytology. Pathologists evaluated the slides and gave the reports.

Results

The present series consisted of 32 patients; 8 (25%) females and 24 (75%) males. The age of the patients varied from 18

years to 75 years, with the majority over 40 years. The majority of patients presented with complaints of cough with expectoration, hemoptysis, fever and breathlessness. A few of them complained of weight loss, loss of appetite, hoarseness of voice, chest pain and had features suggestive of pleural effusion. Analysis of radiological findings among patients who were included in the study showed that 19 patients (59.38%) had collapse on right side and 13 patients (40.62%) had collapse on left side. Analysis of chest X-ray findings among patients who were included in the study showed that, right upper lobe was involved in 3 patients(15.79%), right middle lobe was involved in 7 patients (36.84%), right lower lobe was involved in 3 patients (15.79%), right total lung was involved in 6 patients (31.59%), left upper lobe was involved in 4 patients (30.77%), left lower lobe was involved in 3 patients (23.07%)and left total lung was involved in 6 patients (46.15%). Analysis of duration of symptoms among patients who were included in the study showed that the majority of patients (50%) presented to hospital in <1 month of onset of symptoms. 3 patients (10%) between 1-2months and 12 patients (40%) after 2 months of onset of symptoms. A suspicion of malignancy was the indication in 25 (78.57%) cases while infectious causes were the clinical diagnosis in the rest. The bronchoscopic findings included presence of an endobronchial growth 18(56.25%), unhealthy mucosa 4(12.5%), external compression 4(12.5%) and stenosis in 6(18.75%) cases. On histological examination, the cases were broadly classified as being neoplastic 18 (56.25%) and non-neoplastic 14(43.75%) (Table 1).

Table 1: Diagnosis and distribution of various lesions confirmed by bronchial biopsy

Neoplastic	18 Squamous cell carcinoma =12 Adenocarcinoma =05 Small cell carcinoma =1
Tubercular	7
Pneumonia	1
Fungal	2
Inadequate tissue	4

In the neoplastic category, squamous cell carcinoma accounted for majority of the tumors (12 cases) and five cases were diagnosed as adenocarcinoma. There was one case of small cell carcinoma. Out of the 14 patients in the non-neoplastic category, granulomatous diseases formed the majority (70% cases). Brushings, washings and biopsies were done in all the 32 cases. Washings were positive in only 11 cases out of 32 with sensitivity of only 52.38% and a specificity of 70%. Positive predictive value was 78.57% while negative predictive value was 38.88%. Hence, the results were not very encouraging (Table 2). Brushings were positive in 18 cases out of 32 with sensitivity of 85.71% and a specificity of 90.90%. The positive predictive value was 94.73% while the negative predictive value was 76.92% (Table 3). Based on the presence of caseation necrosis, acid-fast bacilli and reticulin stains, tuberculosis was diagnosed in seven patients. Further typing of four cases could not be done due to inadequate sample. In the inflammatory group,

three were diagnosed infection with one pneumonia and two Aspergillus. The branching fungal hyphae were seen within the areas of necrosis.

Table 2: Test Results

Sample	Test Results				
	TP	TN	FP	FN	Total
Bronchial wash	11	7	3	11	32
Bronchial brush	18	10	1	3	32

TP: True Positive, TN: True Negative, FP: False Positive, FN: False Negative

Table 3: Comparison of bronchial washings and brushings

	Washings	Brushings
Specificity	52.38	85.71
Sensitivity	70	90.90
Positive Predictive Value (PPV)	78.57	94.73
Negative Predictive Value NPV	38.88	76.92

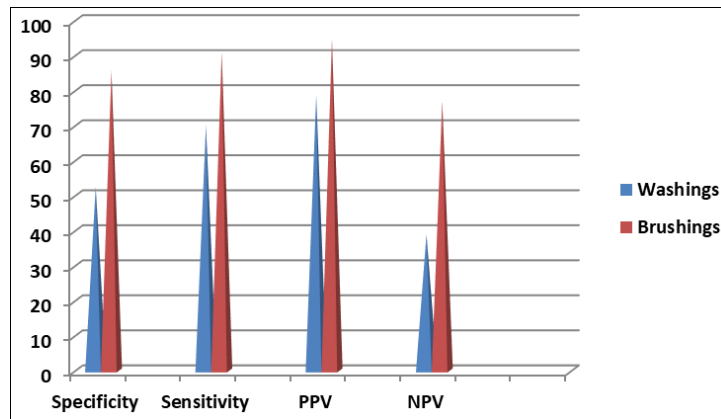


Fig 1: Comparison of bronchial washings and brushings

Discussion

Collapse is an important sign of pulmonary disease therefore it is necessary to use diagnostic tools such as fiberoptic bronchoscopy to get an accurate diagnosis of underlying cause in a patient presenting with collapse on chest radiograph or CT-Chest. The major causes of collapse of lung include lung cancer, endobronchial tuberculosis, infection, endobronchial metastasis, bronchiectasis, foreign body, mucous plug etc. [5]. The most common cause of lobar collapse is obstruction by a central endobronchial lesion.

The earliest manifestation of tumors that arise in the proximal airways is frequently the result of airway obstruction rather than the tumors themselves. In fact, radiographic findings secondary to airway obstruction are present in approximately 40% of patients of initial evaluation. The most frequent of these findings include collapse, bronchiectasis with mucous plugging, and consolidation [6].

In an adult with collapse, a central obstructing neoplasm should always be considered as the underlying cause. Bronchogenic carcinoma is relatively uncommon in adults under the age of 40, when bronchial carcinoid tumor is more likely [7] around three-quarters of primary lung tumors can be visualized directly using a flexible bronchoscope. Bronchial biopsies and brush samples can be taken for pathological examination and a direct assessment can be made of operability as judged by the proximity of central tumors to the main carina [8]. 10–40% of patients with active pulmonary tuberculosis have endobronchial tuberculosis. 25–35% of endobronchial tuberculosis patients present as collapse on chest radiograph. Bronchoscopy is a valuable tool in diagnosing endobronchial tuberculosis.

In the present series, a suspicion of malignancy was the commonest indication for FOB. In our study, adequate tissue, sufficient for reporting, was obtained in 28 (87.5%) cases. These findings are in concordance with a study performed by Hansen *et al.*, [4] in which adequate tissue was obtained in 93% cases which substantiate the fact that with FOB an adequate tissue can be attained and a diagnosis can be established in majority of the cases. On histopathological analysis, neoplastic lesions constituted the majority. Among the neoplasms, squamous cell carcinoma was the commonest tumor. Bronchoscopic examination revealed an endobronchial growth in 18 (56.25%) patients, while the rest had unhealthy mucosa or stenosis. We found a high diagnostic yield with brushing specimen with positive predictive values exceeding 90%. Melanie *et al.*, [9] reported a concordance rate of 97% between bronchial biopsy and

brushings. Hansen *et al.*, [4] reported a positivity of 91% by brushings while Matsuda *et al.*, [10] also gave results similar to our study. On the contrary, washings were found to have a sensitivity of only 52.38% though the specificity was 70%. Thus, negative washing results are not reliable to rule out malignancy. Hadfield *et al.*, [11] too concluded that washings alone are not useful in diagnoses of lung diseases but when positive can give a fairly reliable diagnosis of malignancy. Two cases of Aspergillus infection were also diagnosed. Tuberculous granulomas were found in 7 cases (21.87%). In the suspected non-neoplastic group brushings and washings were not found useful. This was also documented by the American Thoracic Society [12, 13]. In the non-neoplastic category, tuberculosis and was the commonest granulomatous lesions diagnosed by FOB.

Conclusions

We conclude that fiberoptic bronchoscopy can be successfully employed for the diagnosis of patients presenting with collapse of lung/lobe on chest X-ray or CT-Chest lung diseases. Bronchial brushings can very reliably diagnose neoplastic diseases. On the other hand, washings have a very limited role in the diagnosis of cases of lung collapse. In the present study, FOB led to a diagnosis in 90% patients. Most common cause of collapse was malignancy (73.4%). Most common bronchoscopic finding is endobronchial mass 19 patients, (63.4%). However, large scale studies are needed to further define the role of this modality in patients presenting with collapse of lung.

Conflicts of interest: None declared

Acknowledgements: None

References

1. Patterson EJ. History of bronchoscopy and esophagoscopy. *Laryngoscopy*. 1926; 36:157-75.
2. Lee FYW, Mehta AC. *Basic Techniques in Flexible Bronchoscopy*. Cambridge: Blackwell Science, 1995, 95-118.
3. Jindal SK, Behera D, Dhand R, Kashyap S, Malik SK. Flexible fiberoptic bronchoscopy in clinical practice: a review of 100 procedures. *Indian J Chest Dis Allied Sci*. 1985; 27:153-8.
4. Hansen R, Zavala DC, Rhodes ML. Transbronchial lung biopsy via flexible fiberoptic bronchoscopy. *Am Rev Respir Dis*. 1986; 114:112-28.
5. Jain P, Sandur S, Meli Y, Mehta A. Role of fiberoptic bronchoscopy in patients with lung infiltrates. *Chest*.

- 2004; 12:712-22.
6. Faber LP, Fink AI, Murphy DJ. Lung cancer. *Am Cancer Soc J.* 1991; 68:11-23.
 7. Yank P, Allen MS, Aubery MS. Clinical features of 5628 primary lung cancer patients at Mayo Clinic. *Chest.* 2005; 128:452-62.
 8. Pande JN, Sharma SK, Jandon M, Verma K, Guleria JS. Fiberoptic bronchoscopy in the diagnosis of malignant lesions of lung: a 3-year experience. *Indian J Chest Dis Allied Sci.* 1982; 24:244-49.
 9. Melanie K, Diva R, Salamo MD. Diagnostic concordance of lung cancer between bronchial biopsy and cytology. *Arch Pathol Lab Med.* 2010; 134:1504-512.
 10. Matsuda M, Hari T, Nakamura S. Bronchial brushings and biopsy: comparison of diagnostic accuracy and cell typing, reliability in lung cancer. *Clin Pathol.* 1981; 34:773-78.
 11. Hadfield JW, Payne CR, Stevin PG. Diagnostic accuracy of cytology and biopsy in primary bronchial carcinoma. *Clin Pathol.* 1981; 34:773-78.
 12. Gupta D, Behera D, Joshi K, Jindal SK. Role of transbronchial lung biopsy in diagnosis of parenchymal lung diseases. *J Assoc Physicians India.* 1997; 45:371-73.
 13. Kalra S, D'Souza G, Bhusnurmath B, Jindal SK. Transbronchial lung biopsy in diffuse lung disease: a study of 28 cases. *Indian J Chest Dis Allied Sci.* 1989; 31:265-70.