



E-ISSN: 2706-9575

P-ISSN: 2706-9567

IJARM 2021; 3(2): 136-139

Received: 09-05-2021

Accepted: 12-06-2021

Dr. Muni Bhavani Itha
Assistant Professor,
Department of Pathology,
KMCH, Guntur, Andhra
Pradesh, India

Dr. Kalyan Chakravarthy V
Professor, Department of
Pathology, Dr. PSIMS &RF,
Vijayawada, Andhra Pradesh,
India

Corresponding Author:
Dr. Kalyan Chakravarthy V
Professor, Department of
Pathology, Dr. PSIMS &RF,
Vijayawada, Andhra Pradesh,
India

Retroperitoneal Leiomyosarcoma: A rare case report with immunohistochemistry findings

Dr. Muni Bhavani Itha and Dr. Kalyan Chakravarthy V

DOI: <https://doi.org/10.22271/27069567.2021.v3.i2c.230>

Abstract

The majority of soft tissue tumors are present in the extremities; however, many other sites can be affected, including the retroperitoneum. Retroperitoneal tumors represent a rare entity, and sarcomas are the most commonly seen tumors. Sarcomas are mesenchymal in origin; they arise from skeletal and extra skeletal connective tissues, including the peripheral nervous system. In a population-based series reported in the SEER database, the average annual incidence of retroperitoneal sarcomas was approximately 2.7 cases per million populations. Leiomyosarcomas are second in frequency at this location and are also the most aggressive of the sarcomas.

Here we reported a case of a 48-year-old female, who presented with a left-sided abdominal lump associated with pain. Abdominal imaging showed a retroperitoneal tumor-infiltrating the ureter. Histopathological examination of the excised mass showed features of malignant retroperitoneal tumor with the possible differential diagnosis included 1. Leiomyosarcoma, 2. Malignant Peripheral Nerve Sheath Tumor.

Advised immunohistochemistry, for further evaluation and confirmation. Immunohistochemistry with a panel of antibodies confirmed the case as Retroperitoneal Leiomyosarcoma.

Keywords: Retroperitoneum, leiomyosarcoma, soft tissue sarcoma

Introduction

We reported a case of 48-year-old female patient presented with complaints of pain abdomen with discomfort, increased abdominal girth, and weight loss of four months duration.

On physical examination, an abdomen lump was felt in the left lumbar region, and the patient was advised for ultrasonography abdomen and intravenous pyelogram.

Ultrasonography (USG) abdomen revealed a mixed echogenic lobulated mass in the left lumbar region ~ measuring 9 x 10 cms, and left renal hydronephrosis was noted up to mid ureter. Intravenous pyelogram (IVP) revealed non-functioning left kidney and normally appearing right pelvicalyceal system & ureter.

The patient was referred to MRI abdomen and pelvis for further evaluation of the lumbar mass, visualized in USG examination. Axial & Coronal MRI abdomen revealed a large lobulated mixed intensity (solid and cystic component) soft tissue mass measuring 12x8x5 cms in the retroperitoneum, infiltrating the left ureter resulting in left hydronephrosis, and the mass was seen to displaced the bowel anteriorly [Figure 1]. The patient underwent exploratory laparotomy, and the excised retroperitoneal mass was sent for histopathological examination.

Macroscopic examination of the tumor mass revealed round to oval soft tissue mass measuring 10x6x4cms, greyish brown in color, and solid consistency. Cut section showed whorled appearance admixed with focal myxoid and necrotic areas [Figure 2].

Histopathological examination of the excised mass [Figure 3] revealed malignant retroperitoneal tumors with high cellularity, spindle-shaped stromal cells arranged in fascicles exhibiting nuclear atypia, more than ten mitoses per 50 HPF, focal myxoid degeneration, and necrosis. The possible differential diagnosis was given as 1. Leiomyosarcoma 2. Malignant Peripheral Nerve Sheath Tumor. French Federation of Cancer Centers Sarcoma Group grading system (FNCLCC) grade 2. Advised immunohistochemistry for further evaluation and confirmation.

Immunohistochemistry was performed with a panel of antibodies (Vimentin, Smooth Muscle Actin (SMA), S-100, CD117, CD34 markers). On immunohistochemistry, spindle cells exhibited positive staining for Vimentin and Smooth Muscle Actin (SMA) [Figure 4a &4b]. The spindle tumor cells showed negative staining for CD34, CD117, S-100

markers. Vimentin positivity indicates the tumor's mesenchymal origin, and the SMA positivity indicating the smooth muscle origin of the tumor cell. So the final diagnosis of Leiomyosarcoma of retroperitoneal origin was made [Figure 4].

Figure 1: MRI abdomen and pelvis: Large soft tissue opacity mass in the left lumbar region.

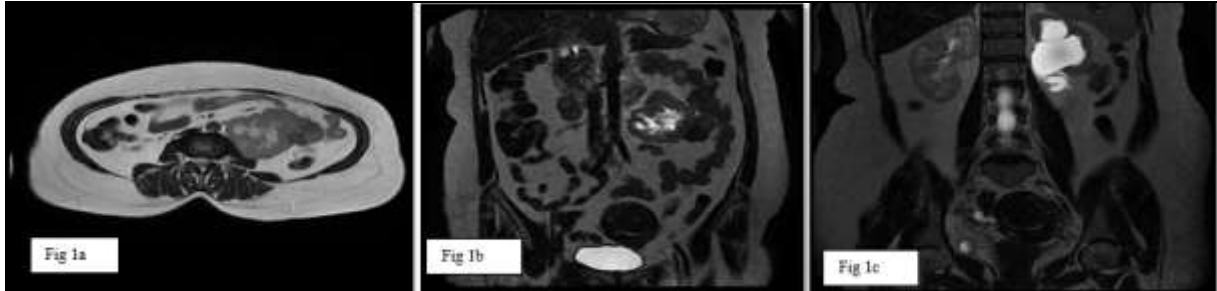


Fig 1: (a, b, c) Axial & Coronal MRI of abdomen and pelvis: Large lobulated mixed intensity (solid and cystic component) soft tissue mass 12x8x5 cms in the retroperitoneum, infiltrating the left ureter resulting in left hydro-ureteronephrosis and the mass is seen to displaced the bowels

Figure 2: Macroscopic examination of the excised mass

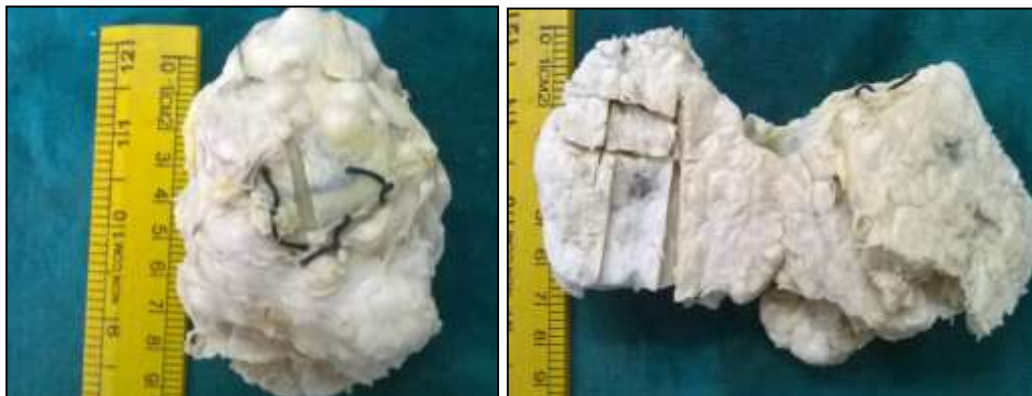

Fig 2: Macroscopic examination of retroperitoneal mass revealed well circumscribed, solid, greyish brown soft tissue mass measuring 10x6x4cms, on cut section showed whorled appearance, focal necrotic and myxoid areas.

Figure 3: Histopathological examination of the excised mass

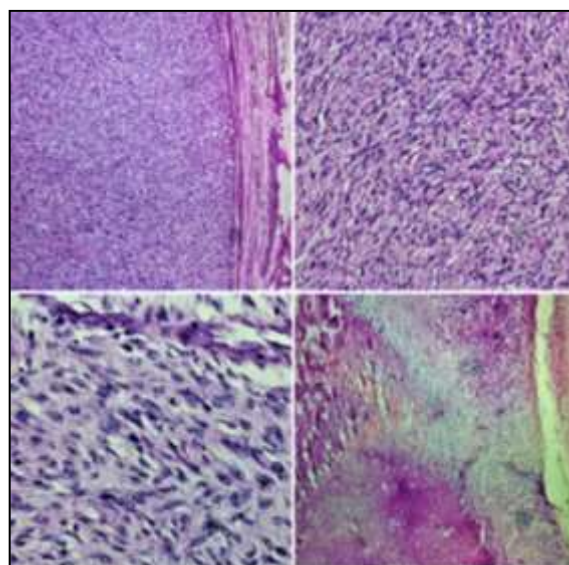


Fig 3: Photomicrograph of leiomyosarcoma showing pleomorphic, hyperchromatic spindle shaped tumour cells arranged in fascicular pattern and focal areas of palisading of nuclei with necrotic and myxoid areas.

Figure 4: Immunohistochemistry (SMA and Vimentin Markers)

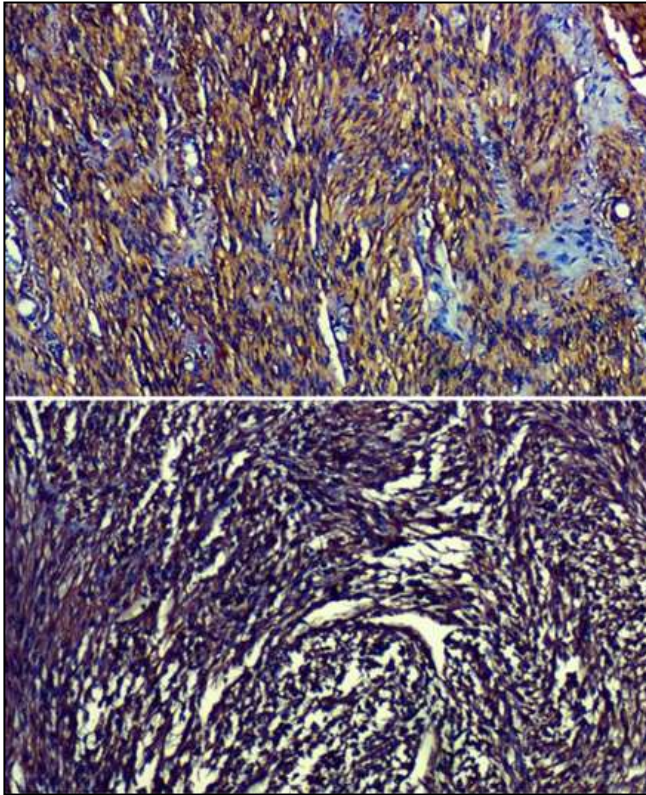


Fig 4: Photomicrograph showing positive cytoplasmic staining with SMA and Vimentin

Discussion

Soft tissue sarcomas are rare malignant tumors of mesenchymal origin, and these tumors can occur in almost any anatomic location. They represented only 0.64 percent of all new cancers in the United States in 2006 [1]. Ten to twenty percent of soft tissue sarcomas occur in the retroperitoneum [2, 6]. In a population-based series reported in the Surveillance, Epidemiology and End Results (SEER) database, the average annual incidence of retroperitoneal sarcomas was approximately 2.7 cases per million population [7].

The most common histologic types of retroperitoneal sarcomas are Leiomyosarcoma, liposarcoma, and fibrosarcoma [2, 6]. Leiomyosarcoma is a malignant mesenchymal tumor of smooth muscle origin [8]. Retroperitoneal leiomyosarcomas may arise from smooth muscle tissue located in the retroperitoneum or the walls of the large retroperitoneal veins [9]. The retroperitoneum represents a sophisticated anatomical space with multiple vital structures and provides a widely expansile anatomical location for tumors arising there. These tumors often become very large before symptoms manifest [6].

Retroperitoneal Leiomyosarcoma occurs most commonly in the fifth to seventh decades of life [2, 5]. The age of our patient was consistent with previous reports. Retroperitoneal tumors often have non-specific presenting symptoms. Usually, a painless, gradually enlarging mass lesion with a median size of 15 to 18 cm is one of the most common findings at diagnosis [10]. In the present case, the patient presented with pain abdomen, discomfort, increased abdominal girth, and weight loss. A case report by Poudel R *et al.* [11] the patient presented with pain in epigastric region

and abdominal lump, and the study by Todd *et al.* [6] the most common clinical presentation of retroperitoneal sarcoma at presentation includes abdominal pain and weight loss accounting for 37.5% for each.

The diagnosis and treatment of retroperitoneal soft tissue sarcomas are challenging because the tumors are relatively rare and frequently present with locally advanced stages. The diagnostic challenges include precise localization of the lesion, determination of the extent of invasion, and characterization of the specific pathologic type. Computed tomography (CT) and magnetic resonance (MR) imaging play an essential role in characterization (size, shape, wall thickness, septa, calcification, and fat content) and the assessment of the extent of the disease and involvement of adjacent and distant structures [12, 13, 14]. A study by Todd *et al.* reported that CT was the preferred method for evaluation of a retroperitoneal mass prior to exploratory laparotomy. In our study, the diagnosis of a retroperitoneal tumor is aided by imaging studies that contribute greatly to knowing the mass's tumor size, location, and character.

Complete surgical resection with at least 3 cm margins is the treatment of choice but is rarely feasible due to invasion of adjacent structures by the tumor [6]. However, In our case report, also complete surgical resection was done.

Grossly, leiomyosarcomas can be as well-circumscribed as the leiomyomas but are larger and softer and have a tendency for fresh tumor necrosis, hemorrhage, and cystic degeneration [15]. Therefore, in our case report also, macroscopic findings were consistent with the above-mentioned findings.

Microscopically, in Leiomyosarcoma, the growth pattern is predominantly fascicular, with the tumor bundles intersecting each other at wide angles. The merging of tumor cells with blood vessel walls is an important diagnostic clue. The individual cells have elongated, blunt-ended nuclei and acidophilic fibrillary cytoplasm, cytoplasmic vacuoles located at both ends of the nucleus, sometimes indenting them, represent another diagnostic clue. In addition, myxoid changes, inflammatory changes, and osteoclast-like multinucleated giant cells may be prominent [15]. In our case report, microscopic examination showed intersecting bundles of smooth muscle cells arranged in a fascicular pattern. The individual tumor cells have elongated blunt-ended nuclei, nuclear atypia, mitotic figures, myxoid changes, and inflammatory cell collections are the diagnostic clues for the diagnosis of Leiomyosarcoma.

Leiomyosarcomas can be graded using the Federation Nationale des Centres de Lutte Contre le Cancer (FNCLCC) or National Cancer Institute (NCI) systems. Both the FNCLCC and NCI systems are soft-tissue sarcoma classification systems rather than specific leiomyosarcoma grading systems. The FNCLCC system uses scores for tumor differentiation, degree of necrosis, and mitotic count to determine the overall tumor grade. The NCI system uses histologic type and subtype, location, amount of tumor necrosis, degree of pleomorphism, and mitotic activity to determine tumor grade. Tumor grades range from 1 to 3 with both systems. The histologic subtypes of Leiomyosarcoma used in these grading systems include well-differentiated Leiomyosarcoma, conventional Leiomyosarcoma, and poorly differentiated/ pleomorphic/ epithelioid Leiomyosarcoma [16, 18]. In our case report, the FNCLCC grade was 2.

The most useful immunohistochemical smooth muscle markers, are Smooth Muscle Actin (SMA), Desmin, and h-Caldesmon [19]. These markers are positive in more than 70% of cases. Since these markers are not entirely specific for smooth muscle, two positive markers are more supportive of the diagnosis of Leiomyosarcoma than one positive marker. Additionally, focal positivity for keratin, epithelial membrane antigen, CD34, and S100 protein may be seen. CD117 (KIT), a marker for gastrointestinal stromal tumors, is negative [8]. In our case report, Vimentin cytoplasmic positivity indicates the mesenchymal tissue origin, and SMA positivity indicates the tumor's smooth muscle origin. Finally, the diagnosis of retroperitoneal Leiomyosarcoma was made after histopathology and immunohistochemistry report.

Conclusion

Retroperitoneal tumors are relatively rare tumors and usually present in a locally advanced stage. Therefore, the diagnosis and the treatment of retroperitoneal soft tissue sarcomas remain challenging. Radiological imaging plays a vital role in diagnosing the tumour location and its relation to other structures, operative planning, and follow-up of patients with retroperitoneal leiomyosarcoma. Complete surgical removal with negative margins remains the mainstay of the treatment. However last but not least, histopathological examination and immunohistochemistry plays an ultimate role to narrow down the differential diagnosis and coming to an accurate diagnosis of Leiomyosarcoma.

References

- Jemal A, Siegel R, Ward E, Murray T, Xu J, Thun MJ. Cancer statistics, CA Cancer J Clin 2007;57:43-66.
- Adam Y, Osland J, Harvey A, Reif R. Primary retroperitoneal soft-tissue sarcomas. J Surg Oncol 1984;25:8-11.
- Cody HS, Turnball AD, Fortner JG, Hajdu SI. The continuing challenge of retroperitoneal sarcomas. Cancer 1981;47:2147-52.
- McGrath PC, Neifeld JP, Lawrence Jr WA, DeMay RM, Kay SA, Horsley 3rd JS, *et al.* Improved survival following complete excision of retroperitoneal sarcomas. Annals of surgery 1984;200(2):200.
- Catton CN, O'Sullivan B, Kotwall C, Cummings B, Hao Y, Fornasier V. Outcome and prognosis in retroperitoneal soft tissue sarcoma. Int J Radia Oncol 1994;29(5):1005-10.
- Todd CS, Michael H, Sutton G. Retroperitoneal leiomyosarcoma: eight cases and a literature review. Gynecologic oncology 1995;59(3):333-7.
- Dalal KM, Kattan MW, Antonescu CR, Brennan MF, Singer S. Subtype specific prognostic nomogram for patients with primary liposarcoma of the retroperitoneum, extremity, or trunk. Annals of surgery 2006;244(3):381-91.
- Fletcher CDM, Bridge JA, Hogendoorn PCW, Mertens F. WHO classification of tumours of soft tissue and bone. Lyon, France: IARC 2013.
- Hartman DS, Hayes WS, Choyke PL, Tibbetts GP. From the archives of the AFIP: Leiomyosarcoma of the retroperitoneum and inferior vena cava—radiologic-pathologic correlation. Radio Graphics 1992;12(6):1203-1220.
- Hassan I, Park SZ, Donohue JH, Nagorney DM, Kay PA, Nasciemento AG, *et al.* Operative management of primary retroperitoneal sarcomas: a reappraisal of an institutional experience. Annals of surgery 2004;239(2):244-50.
- Poudel R, Adhikari SK, Basnet S, Acharya A, Pokhrel S. Unusual Case of Retropancreatic Mass Involving Portal Vein. Journal of Universal College of Medical Sciences 2017;5(2):49-52.
- Neville A, Herts BR. CT characteristics of primary retroperitoneal neoplasms. Crit Rev Comput Tomogr 2004;45(4):247-270.
- Nishino M, Hayakawa K, Minami M, Yamamoto A, Ueda H, Takasu K. Primary retroperitoneal neoplasms: CT and MR imaging findings with anatomic and pathologic diagnostic clues. Radio Graphics 2003;23(1):45-5.
- Nishimura H, Zhang Y, Ohkuma K, Uchida M, Hayabuchi N, Sun S. MR imaging of soft-tissue masses of the extraperitoneal spaces. Radio Graphics 2001;21(5):1141-1154.
- Juan Rosai. Rosai and Ackerman's Surgical Pathology. volume 2. 10th ed. Elsevier 2011, 2163 -65.
- Guillou L, Coindre JM, Bonichon F, *et al.* Comparative study of the National Cancer Institute and French Federation of Cancer Centers Sarcoma Group grading systems in a population of 410 adult patients with soft tissue sarcoma. J Clin Oncol 1997;15(1):350-362.
- Coindre JM. Grading of soft tissue sarcomas: review and update. Arch Pathol Lab Med 2006;130(10):1448-1453.
- Hasegawa T. Histological grading and MIB-1 labeling index of soft-tissue sarcomas. Pathol Int 2007;57(3):121-125.
- Bathan AJ, Constantinidou A, Pollack SM, Jones RL. Diagnosis, prognosis, and management of Leiomyosarcoma: recognition of anatomic variants. Current opinion in oncology 2013;25(4):384-9.